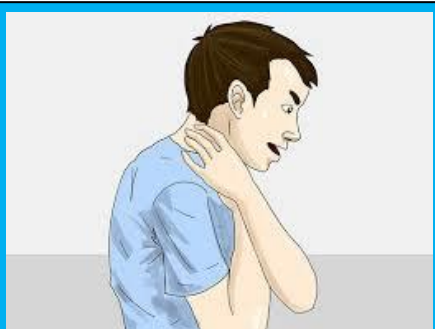



# Airway Obstruction

Dr. Ali D. Abbas/ Instructor, Fundamentals of Nursing Department, College of Nursing, University of Baghdad, ali\_dukhan@yahoo.com

## LEARNING OBJECTIVES

After mastering the contents of this lecture, the student should be able to:

1. Describe the pathophysiology of airway obstruction
2. Describe the causes of airway obstruction
3. Explain the clinical manifestations of airway obstruction
4. List the assessment and diagnostic findings of airway obstruction
5. Describe the management of airway obstruction

## TERMINOLOGIES

Abdominal Thrusts

Acute upper airway obstruction

Cricothyroidotomy

Endotracheal Intubation

Laryngeal Mask Airway

Orpharyngeal airway

Ventilator

# ***CONTENTS***

1. Airway Obstruction

2. Pathophysiology

3. Causes of Upper airway obstruction

4. Clinical Manifestations

5. Assessment and Diagnostic Findings

6. Management

7. Establishing an airway

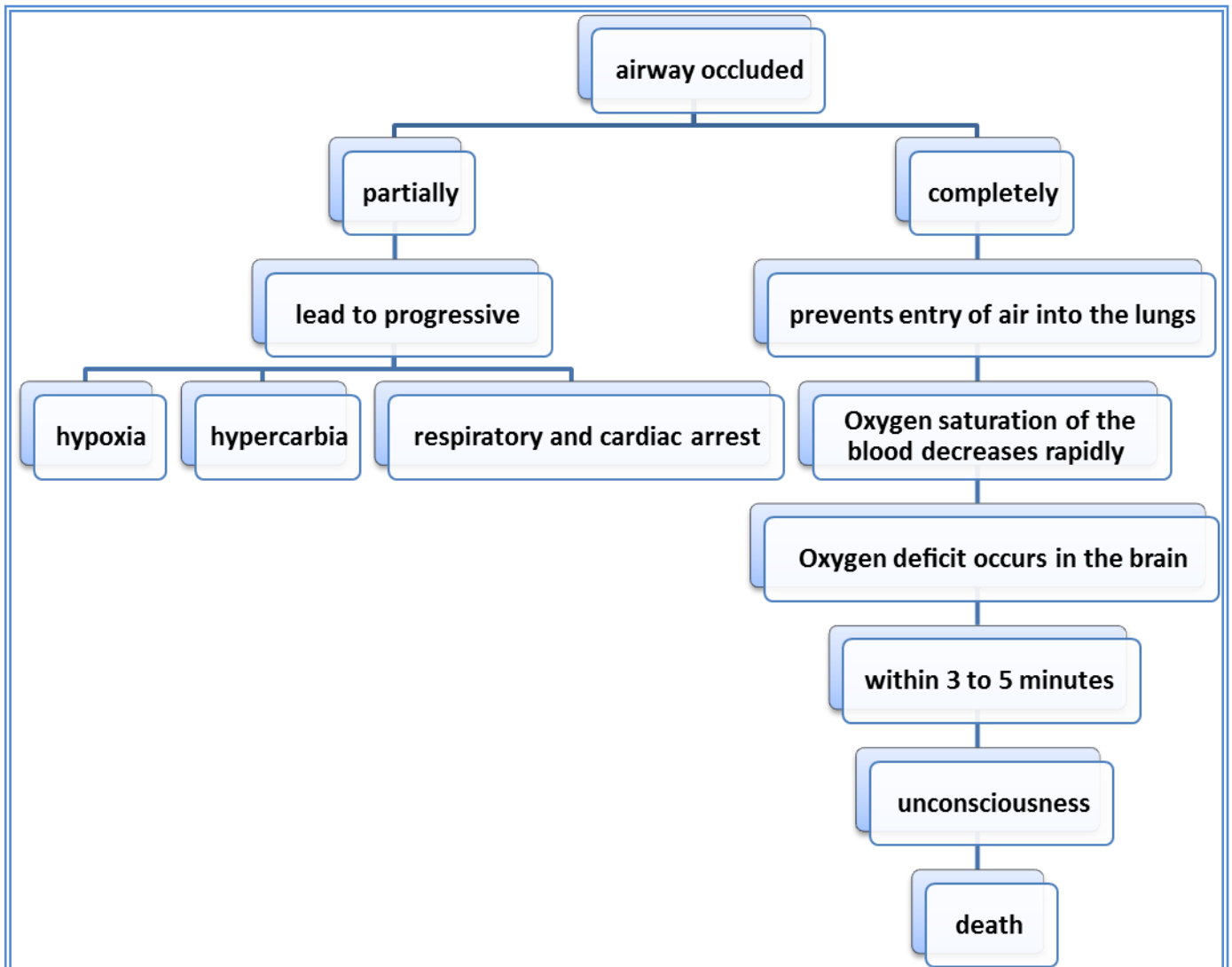
8. Maintaining Ventilation

9. References

## 1. AIRWAY OBSTRUCTIONA

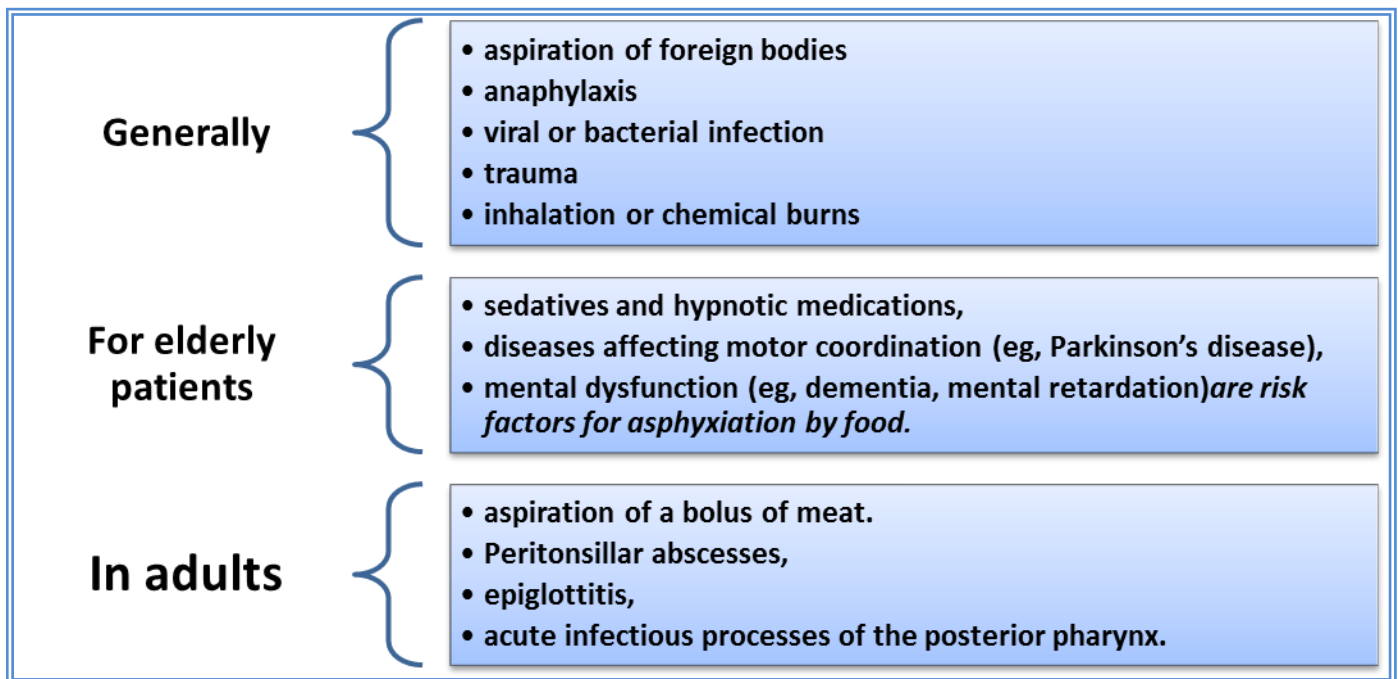
Acute upper airway obstruction is a life threatening medical emergency.

## 2. Pathophysiology: (Figure.1)



(Figure.1)

### 3. Causes of Upper airway obstruction: (Figure.2)



(Figure.2)

### 4. Clinical Manifestations:

1. Cannot speak, breathe, or cough.
2. The patient may clutch the neck between the thumb and fingers (ie, universal distress signal).
3. Choking,
4. Apprehensive appearance,
5. Refusing to lie flat,
6. Inspiratory and expiratory stridor,
7. Labored breathing,
8. Use of accessory muscles(suprasternal and intercostal retraction),
9. Flaring nostrils,
10. Increasing anxiety, restlessness, and confusion.
11. Cyanosis and loss of consciousness are late signs.

### 5. Assessment and Diagnostic Findings:

1. Simply asking the person whether he or she is choking and requires help.
2. If the person is unconscious, inspection of the oropharynx may reveal the offending object.
3. X-rays, laryngoscopy, or bronchoscopy also may be performed.

## 6. Management:

1. If the patient can breathe and cough spontaneously (a partial obstruction).

*The victim is encouraged to cough forcefully and to persist with spontaneous coughing and breathing efforts as long as good air exchange exists. There may be some wheezing between coughs.*

2. If the patient demonstrates a weak, ineffective cough, high-pitched noise while inhaling, increased respiratory difficulty, or cyanosis, (complete airway obstruction).

*After the obstruction is removed, rescue breathing is initiated.*

3. If the patient has no pulse, *cardiac compressions are instituted.*

*These measures provide oxygen to the brain, heart, and other vital organs until definitive medical treatment can restore and support normal heart and ventilator activity.*

## 7. Establishing an airway:

1. Simple as repositioning the patient's head to prevent the tongue from obstructing the pharynx.
2. Other maneuvers (abdominal thrusts, the head-tilt–chin-lift maneuver, the jaw-thrust maneuver)
3. Insertion of specialized equipment may be needed to open the airway, remove a foreign body, or maintain the airway.

*Note 1 / in all maneuvers, the cervical spine must be protected from injury.*

*Note 2/ after these maneuvers are performed, the patient is assessed for breathing by watching for chest movement and listening and feeling for air movement.*

### Nursing diagnoses:

- a. *ineffective airway clearance* related to obstruction of the airway by the tongue, an object, or fluids (blood, saliva)
- b. *ineffective breathing pattern* related to airway obstruction or injury.

## Abdominal Thrusts (sub diaphragmatic abdominal thrusts, Heimlich maneuver):

This maneuver causes:

1. Elevation of the diaphragm.
2. Forcing air from the lungs to create an artificial cough that can move and expel an obstructing foreign body from the airway. (Figure.3)

### Managing a Foreign Body Airway Obstruction

#### Assess for Indications of Airway Obstruction

- Person may clutch the neck between thumb and fingers
- Weak, ineffective cough; high-pitched noises on inspiration
- Increased respiratory distress
- Inability to speak, breathe, or cough
- Collapse

#### Heimlich Maneuver (Subdiaphragmatic Abdominal Thrusts)

##### For Standing or Sitting Conscious Patient

Stand behind the patient, wrap your arms around the patient's waist, and proceed as follows:

1. Make a fist with one hand, placing the thumb side of the fist against the patient's abdomen, in the midline slightly above the umbilicus and well below the xiphoid process. Grasp the fist with the other hand.
2. Press your fist into the patient's abdomen with a quick inward and upward thrust. Each new thrust should be a separate and distinct maneuver. All thrusts should be in rapid sequence.

##### For Patient Lying Down (Unconscious)

1. Position patient on the back.
2. Kneel astride the patient's thighs, facing the head.
3. Place the heel of one hand against the patient's abdomen, in the midline slightly above the umbilicus and well below the tip of the xiphoid; place the second hand directly on top of the first.
4. Press into the abdomen with a quick upward thrust. All thrusts should be in rapid sequence.

##### Finger Sweep

1. Open the adult patient's mouth by grasping both the tongue and lower jaw between the thumb and fingers and lifting the mandible (tongue-jaw lift). This maneuver is to be used *only in the unconscious adult patient*. This action

draws the tongue away from the back of the throat and away from the foreign body that may be lodged there.

2. If a foreign body is visible in the mouth, insert the index finger of the other hand down along the inside of the cheek and scrape across the back of the throat.
3. Use a hooking action to dislodge the foreign body and maneuver it into the mouth for removal. Care is used to avoid forcing the object deeper into the throat.

##### Chest Thrusts With Conscious Patient Standing or Sitting

This technique is to be used *only in the patient in advanced stages of pregnancy or in the markedly obese person*.

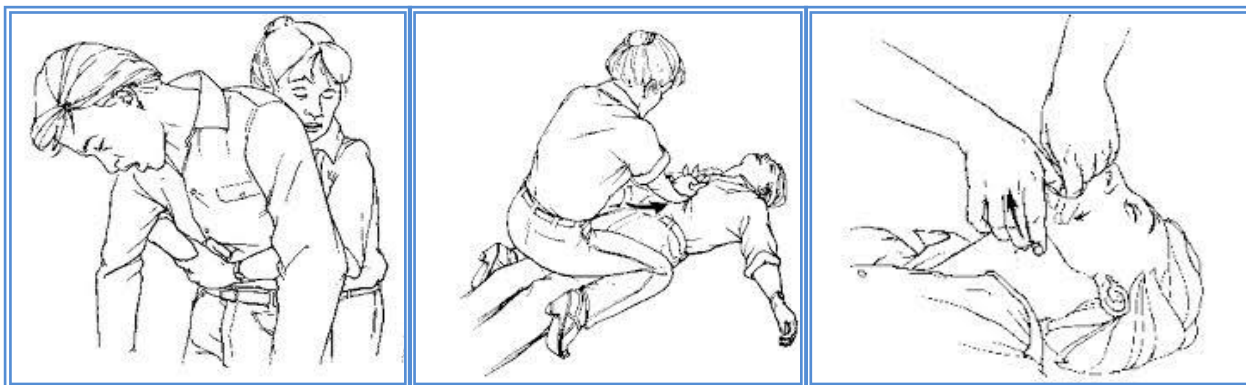1. Stand behind the patient with your arms under the patient's axillae to encircle the patient's chest.
2. Place the thumb side of your fist on the middle of the patient's sternum, taking care to avoid the xiphoid process and the margins of the rib cage.
3. Grasp your fist with the other hand and perform backward thrusts until the foreign body is expelled or the patient becomes unconscious. Each thrust should be administered with the intent of relieving the obstruction. All thrusts should be in rapid sequence.

##### Chest Thrust With Patient Lying (Unconscious)

This maneuver is used *only in the patient in advanced stages of pregnancy or when the rescuer cannot apply the Heimlich maneuver effectively to the unconscious, markedly obese person*.

1. Place the patient on the back and kneel close to the side of the patient's body.
2. Place the heel of your hand on the lower half of the sternum.
3. Deliver each chest thrust slowly and distinctly with the intent of relieving the obstruction.

Adapted from American Heart Association. (2005). BLS for healthcare providers. Available at: [www.americanheart.org](http://www.americanheart.org).

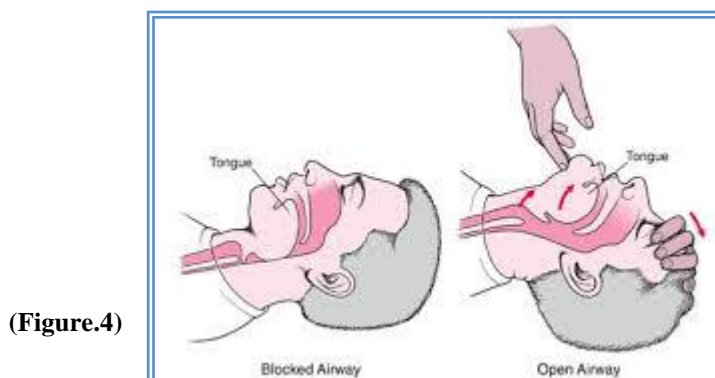


(Figure.3)

### Head-Tilt–Chin-Lift Maneuver:

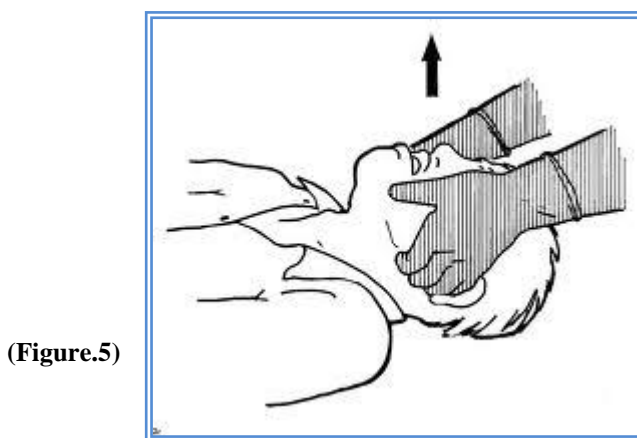
1. The patient is placed supine on a firm, flat surface.
2. If the patient is lying face down, the body is turned as a unit so that the head, shoulders, and torso move simultaneously with no twisting (ie, logroll).
3. The airway is opened using either the head-tilt–chin-lift maneuver or the jaw thrust maneuver.

**a. In the head-tilt–chin-lift maneuver**, one hand is placed on the victim’s forehead, and firm backward pressure is applied with the palm to tilt the head back. The fingers of the other hand are placed under the bony part of the lower jaw near the chin and lifted up. The chin and the teeth are brought forward almost to occlusion to support the jaw. (Figure.4)



**Note** / The head-tilt–chin-lift maneuver, which helps tilt the head back, should be used only if it is determined that the patient’s cervical spine is not injured.

**b. In the Jaw-Thrust Maneuver**, after one hand is placed on each side of the patient’s jaw, the angles of the patient’s lower jaw are grasped and lifted, displacing the mandible forward. (Figure.5)



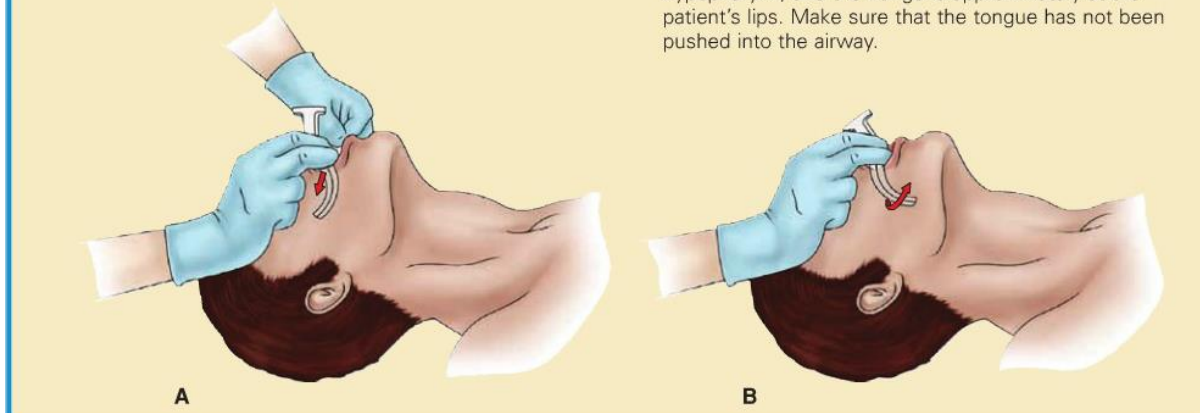
**Note** / This is a safe approach to opening the airway of a patient with suspected spinal cord injury because it can be accomplished without extending the neck.

### Oropharyngeal Airway Insertion:

An oropharyngeal airway is a semicircular tube or tube like plastic device that is inserted over the back of the tongue into the lower posterior pharynx in a patient who is breathing spontaneously but who is unconscious.

### Inserting an Oropharyngeal Airway

1. Measure the oral airway alongside the head. The airway should reach from lip to ear.
2. Extend the patient's head by placing one hand under the bony chin (*only if the cervical spine is uninjured*). With the other hand, tilt the head backward by applying pressure to the forehead while simultaneously lifting the chin forward.
3. Open the patient's mouth.
4. **(A)** Insert the oropharyngeal airway with the tip facing up toward the roof of the mouth until it passes the uvula. **(B)** Rotate the tip 180 degrees so that the tip is pointed down toward the pharynx. This displaces the tongue anteriorly, and the patient then breathes through and around the airway.
5. The distal end of the oropharyngeal airway is in the hypopharynx, and the flange is approximately at the patient's lips. Make sure that the tongue has not been pushed into the airway.

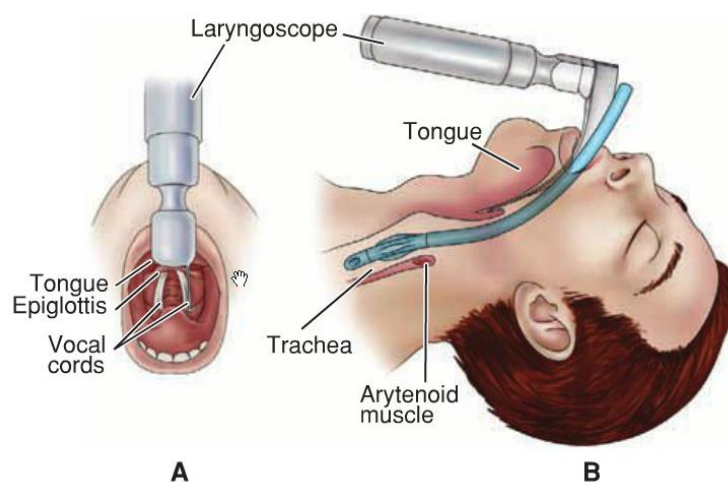


**Note/** This type of airway prevents the tongue from falling back against the posterior pharynx and obstructing the airway. It also allows health care providers to suction secretions.

### Endotracheal Intubation:

Endotracheal intubation is indicated to:

1. Establish an airway for a patient who cannot be adequately ventilated with an oropharyngeal airway.
2. Bypass an upper airway obstruction
3. Prevent aspiration
4. Permit connection of the patient to a resuscitation bag or mechanical ventilator
5. Facilitate the removal of tracheobronchial secretions. **(Figure.6)**



Endotracheal intubation in a patient without a cervical spine injury. **A**, The primary glottic landmarks for tracheal intubation as visualized with proper placement of the laryngoscope. **B**, Positioning the endotracheal tube.

**(Figure.6)**

## Intubation with a Combitube or Laryngeal Mask Airway:

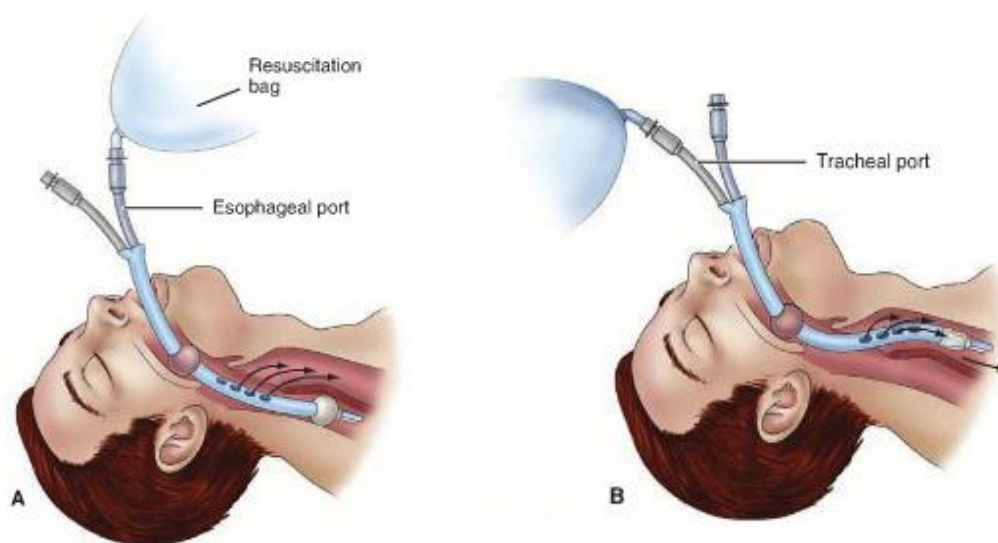
If the patient is not hospitalized and cannot be intubated in the field, emergency medical personnel may insert a Combitube, which rapidly provides pharyngeal ventilation. When the tube is inserted into the trachea, it functions like an endotracheal tube.

The two balloons that surround the tube are inflated after the tube is inserted:

**One balloon is large** (100 mL) and occludes the oropharynx. This permits ventilation by forcing air through the larynx.

**The smaller balloon** is inflated with 15 mL of air and is supposed to anchor the device in the esophagus at a site distal to the glottis; however, it can occlude the trachea if it is inadvertently placed there.

Breath sounds are auscultated after balloon inflation to make sure that the oropharyngeal balloon (or cuff) does not obstruct the glottis. The patient can be ventilated through either one of the two ports (eg, tracheal or esophageal) of the tube, depending on whether the tube is placed in the trachea or esophagus. (Figure.7)



(Figure.7)

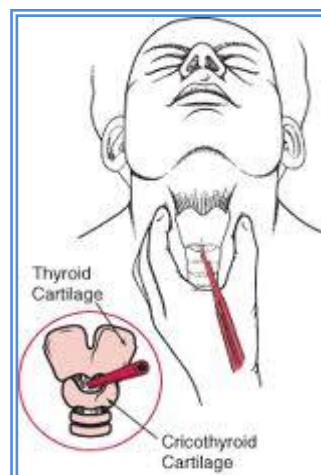
**Note/** If it is difficult to establish an airway, a laryngeal mask airway (LMA) may be inserted as an interim airway device. The design of the LMA provides a “mask” in the subglottic airway with a cuff inflated within the esophagus. It allows easy insertion for rapid airway control until a more definitive airway can be placed.

## Cricothyroidotomy (Cricothyroid Membrane Puncture):

---

Cricothyroidotomy is the opening of the cricothyroid membrane to establish an airway. (Figure.8) This procedure is used in emergency situations in which endotracheal intubation is either not possible or contraindicated, as

1. Extensive maxillofacial trauma
2. Cervical spine injuries
3. Laryngospasm
4. Laryngeal edema
5. Hemorrhage into neck tissue
6. Obstruction of the larynx.



(Figure.8)

**Note** / A cricothyroidotomy is replaced with a formal tracheostomy when the patient is able to tolerate this procedure.

## 8. Maintaining Ventilation (Role of Nurse):

---

1. Ensure that ventilation is adequate by checking for equal bilateral breath sounds.
2. Quickly assess for absent or diminished breath sounds
3. Monitor pulse oximetry, capnography, and arterial blood gases if the patient requires airway or ventilatory assistance.

## 9. References:

---

Smeltzer, S.; Bare, B.; Hinkle, J.; and Cheever, K.: **Textbook of Medical-Surgical Nursing**, 12<sup>th</sup> ed., 2010, Philadelphia: Lippincott Williams and Wilkins .P.P.2158-2161.